

PET: Diagnosing and Staging/Restaging of Lymphoma

Richard S. Feinstein, MD, Mohan Makhija, MD and Jeffrey S. Kempf, MD, FACR

The incidence of malignant lymphoma is approximately 5 new cases per 100,000 persons per year. These include cases of both Hodgkin's disease (HD) as well as the heterogeneous group of non-Hodgkin's lymphomas (NHL). The patient's histology, extent of disease, as well as accurate initial staging are essential for optimizing patient therapy. CT, and more recently MRI, have resulted in significant diagnostic advances in the imaging of both HD and NHL. Although CT is an excellent anatomic imaging technique, the CT criteria for pathologic lymphadenopathy are based on nodal size alone, which is a major limitation. In addition, CT has limited sensitivity for the detection of organ involvement as well as bone marrow involvement.

Many of the limitations of conventional imaging are overcome with FDG-PET. PET imaging measures metabolic activity in malignant tissues and is not reliant on anatomic structural changes alone. There is increased glucose metabolism in most lymphomas — the degree of uptake appears to correlate with the histologic rate of malignancy as well as proliferative rate.

In a review of the literature regarding initial staging, CT and FDG-PET appear to each detect additional nodal sites of disease, compared with each modality alone. However, FDG-PET is superior to CT for detection of extranodal lymphoma, including organ as well as osseous involvement. FDG-PET is more sensitive and specific than bone scintigraphy in patients with lymphoma. FDG-PET reportedly leads to a change of staging in 7% to 16% of patients, and 2 studies have reported a change of therapy in 13% to 14% of cases.

In addition, FDG-PET has recently been shown to be very useful in the restaging of patients with lymphoma. During chemotherapy, PET may identify responders earlier in the course of treatment compared with CT. FDG-PET also appears to better differentiate recurrent tumor or residual masses post-therapy vs. conventional anatomic imaging.

In summary, FDG-PET is recommended for staging patients with lymphoma in addition to CT and other conventional staging modalities because it can detect additional nodal and extranodal lymphomatous lesions as well as bone marrow involvement. In addition, recent studies have shown that FDG-PET can be very useful in monitoring therapy and detection of persistent or recurrent lymphoma. FDG-PET has superior resolution compared with gallium scintigraphy and is replacing gallium for patients with lymphoma.

This 39 year-old man was referred for staging of Hodgkin's lymphoma. A CT scan of the abdomen and pelvis showed a paraduodenal mass and mildly enlarged retroperitoneal lymph nodes. A PET scan showed abnormal activity regional to the paraduodenal mass and retroperitoneal lymph nodes. It also showed abnormal activity involving a paraesophageal mass. This posterior mediastinal mass initially could not be appreciated on the patient's chest CT scan as being separate from the normal esophagus. Thus, the PET scan significantly changed the staging of the patient's disease.

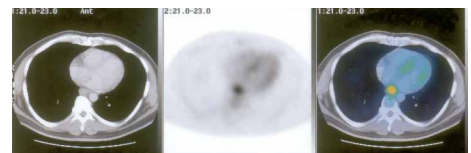

Figure 1a: Fusion of the chest CT and PET transaxial imaging shows an abnormal hypermetabolic focus in the posterior mediastinum.

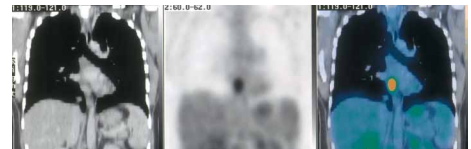

Figure 1b: Fusion of the chest CT and PET coronal imaging shows the abnormal activity in the paraesophageal area.

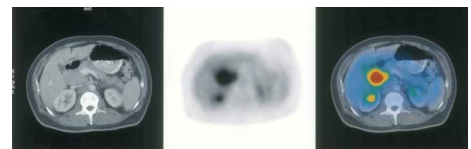


Figure 2: Fusion of the abdomen CT and PET transaxial imaging shows abnormal hypermetabolic activity involving a paraduodenal mass.

If you have any questions or comments, we would be happy to discuss them with you and can be reached by calling 732-246-0060.

Appointments for PET imaging can be scheduled by calling 800-758-5545.